

Original Research Article

Functional Reconstruction of Turbinates with Growth Factors and Adipose Tissue in the Treatment of Empty Nose Syndrome

Lino Di Rienzo Businco, Alessia Di Mario*, Mario Tombolini*, Domenico Crescenzi**, Marco Radici**

Department of Otorhinolaryngology Santo Spirito Hospital, Rome, Italy

** Department of Otorhinolaryngology, Santo Volto Clinic, Rome, Italy*

*** Department of Otorhinolaryngology, S. Giovanni Calibita Hospital, Rome, Italy*

Corresponding author: Dott. Lino Di Rienzo Businco, Via G.B. de Rossi 15A, 00161 Rome, Italy, Tel. +390644202269;

Email: ldrienzo@businco.net

Received: 11-25-2015

Accepted: 12-07-2015

Published: 12-28-2015

Copyright: © 2015

Abstract

Background

Empty nose syndrome (ENS) is a devastating complication of turbinate surgery. The management of ENS is challenging and the evidence base for most treatment modalities remains low. In the present study we propose a safe and effective surgical reconstruction treatment based on the use of Platelet Rich Plasma mixed with Adipose tissue (PRL). The PRL is a preparation rich in stem cells and growth factors, taken from the same patient, that has the potential capability to regenerate the volume of the turbinate and to restore the functionality of the mucosa.

Methodology

46 patients randomly divided in two groups: one group treated with PRL and the other one with medical treatment alone. The aim of the study was to compare the safety and efficacy of the PRL for the treatment of ENS in comparison with medical treatment alone.

Results

Both procedures had no collateral effects but only patients treated with PRL showed a statistically significant improvement ($p < 0.05$) in the subjective nasal symptoms and the endoscopic nasal objectivity after surgery.

Conclusions

Turbinate reconstruction with PRL is a safe, simple and effective procedure characterized by a very low invasiveness with easy availability to autologous biological tissue and no collateral effects.

Keywords: Empty Nose Syndrome, Turbinate, Stem cells, Atrophic Rhinitis, PRP

Introduction

Surgery for turbinate hypertrophy is very common and represents the eighth most frequent procedure employed in the otolaryngological field [1]. Over years numerous surgery techniques for the treatment of inferior turbinate hypertrophy have been proposed, in which the principle problem was to increase the nasal airflow preserving the functions of the mucosal lining, location of important protective activity and of pharmaceutical drug absorption useful in the long term postoperative treatment of submucosal membrane inflammation (turbineotomy, submucosal membrane extraction with or without debrider, cryocoagulation, receptors determines the perception of the passage of air from the nose) [9,10]. Various world specialists have tried to identify a reconstructive surgical technique capable of improving the symptoms of ENS, with encouraging yet partial results; Rice and Di Rienzo Businco with the use of hyaluronic acid [11,12], Yong with inferolateral endonasal cartilage implants [13], and Papay with his fibromuscular temporalis graft implantation [14], but these techniques reveal problems with the reabsorption of the substance used in reconstruction over time. Those problems have been overcome by Jiang with Medpor's implants which is resolute regarding the volume loss but with scarce effectiveness on the recovery of mucosal functionality [15] and by Modrznski with submucosal mono or bipolar electrocauterization, Laser CO and diode, injections of hydroxyapatite on the turbinate and septum [16]. radiofrequencies, coblator, molecular quantum resonance) [1,2]. Before the diffusion of turbinate shrinkage mini-invasive techniques without thermic damage, many of the former techniques (in particular those using high temperatures with old generation radiofrequencies and those extremely demolitive ones with scissors with partial or complete amputations of the turbinate, though they guaranteed an apparent increase of the nasal airflow and a reduction of air resistance to rhinomanometry) were accompanied by a loss of nasal sensitiveness and by the paradoxical reduction of the perception of the air passage with the damage of the mucosal nervous receptors of intranasal anatomy and of the mucosa itself, and by the production of aerial vortices with secondary atrophic rhinitis leading to real 'Empty nose' syndromes (ENS) with crusting, bleeding and synechiae, with a strong negative impact on the quality of the patient's life [1,3,4] ENS, described for the first time by Kern and Stenkvis in 1994, is a rare and highly debilitating pathology, and fortunately not all patients subjected to demolitive surgical intervention on turbinates (inferior or middle) develop this syndrome [5,6]. However, when ENS occurs (this may happen after months or years from demolitive surgery), its symptoms strongly reduce the quality of life, and they can be summarized in: intranasal mucosal dryness, paradoxical nasal breathing obstruction (notwithstanding the large intranasal airspace), facial pains, cephalgia, crusting and altered nasal discharge, with a variability of clinical manifestations which differ according to

patient [5,7].

In these cases of iatrogenic damage with ENS and secondary atrophic rhinitis, the medical therapy (antihistamines, steroids, specific nasal immunotherapy, nasal wash solutions.) prove themselves invariably insufficient to resolve the symptoms of nasal obstruction and inflammations of the patient, with the quality of life considerably reduced and with few possibilities on the doctor's part to improve the local nasal clinical history casefile [8,9]. Even the usual examination tools employed for the evaluation of nasal patency (rhinomanometry, acoustic rhinometry, peak nasal inspiratory flow) are unable to correlate with the clinical symptoms of patients as they do not investigate the physiological mechanisms of the subjective perception of the intranasal airflow (the activation of TRPM8

Also, the studies of AlloDerm (acellular dermal matrix) was proposed by Saafan as having a greater efficacy with respect to silastic implants, yet with partial results when compared with a relatively invasive surgical technique [17]. For some years, plasma enriched with platelets, Platelet Rich Plasma (PRP) have been extensively employed in medicine and surgery for their properties to stimulate an efficient regeneration of both soft tissue and bone tissue (better scar healing and with a reduction in postoperative infections, pain and blood loss) leading these blood components to be routinely used in various branches of surgery and medicine [18,19]. The widespread use of platelet derivatives has certainly proved favourable in their efficacy, combined with an extreme easiness of use and not least in the absence of adverse reactions. Adipose tissue has likewise been the object of great attention these years, for its regenerative potential (above all Stromal Vascular Fraction SVF, Adipose Stem Cells ASC), developed to return volume and functionality, especially in plastic surgery [20-23]. Based on these assumptions, our aim was to verify the efficacy and safety of a new and simple endoscopic infiltrative technique for the reconstruction in patients affected with ENS, of atrophic turbinates and partially amputated, in that they had been coagulated or resected by previous nasal surgery, in addition to a topical medical treatment based on thermal water cleansing and a humidifying vitamin unguent. Such a reconstructive endoscopic surgical technique, different from other methodologies as described in previously published literature which entail intranasal cutting and more invasive implants, is based on the simple injective proceedings in locations of resected turbinates, of PRP mixed with autologous fat [21] taken from a periumbilical extraction (PRL). The fat was purified utilizing Coleman's technique [24,25], and the mixture of PRL thus attained was injected endoscopically into a group of ENS affected patients, comparing the functional results with a group checked with ENS undergoing sole medical therapy. Our aim was to compare the variations of clinical-instrumental parameters and symptoms from the beginning to the end of the treatments - dividing patients into two groups of study, the first (group A), with sole medical pharmaceutical therapy and

the second (group B) with the same medical therapy to which was added an endoscopic treatment with PRL on inferior turbinate regions previously amputated.

Materials and Methods

For the study, 46 patients (39 male) with an age of above 18 years were enrolled consecutively (table 1), following a complete ORL evaluation with physical clinical examination, endoscopy, ConeBeam CT scan of paranasal sinuses, allergy evaluation and SNOT-22 questionnaire, undergoing more than 3 years of treatment in other centers, to turbinectomy or electrocauterization operations of the inferior turbinates owing to their hypertrophy with consequent ENS results (ENS-IT according to the Houser classification) [5]. The ENS diagnosis was supported by the Houser test, which consisted in positioning a pledget soaked in a saline solution in the nasal cavity of patients for 20-30 minutes, revealing their subjective improvement from obstructive symptoms [5]. The criteria for patient inclusion in the study were: failure in every precedent medical test carried out, obstructive nasal symptoms to the VAS greater than 5 (min. 0 – max. 10), and documented resection of the inferior turbinates for a surface equal to or greater than 50% of the endoscopic examination and CT. For the evaluation of damage from inferior turbinate resections our compartmental turbinate classification was utilized so as to objectively quantify the location and the amputated section (Figure 1 and 2) [1].

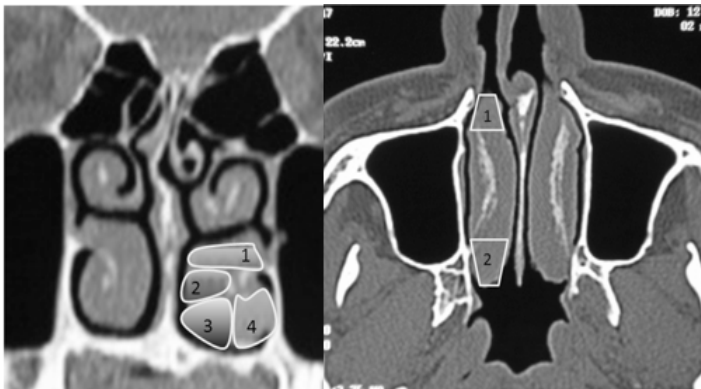


Figure 1. Compartmental classification of the inferior turbinate. On the right: 1 Superior, 2: Middle, 3: Inferior, 4: Infero-lateral On the left: 1: Anterior, 2: Posterior.

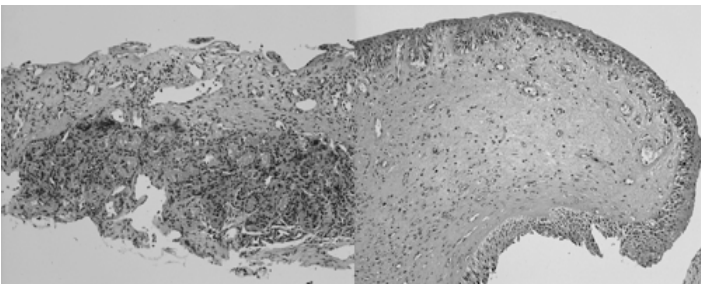


Figure 2. On the right: Turbinate mucosa after turbinectomy

(Ematossilina-Eosina); On the left: Turbinate mucosa after PRL (Ematossilina-Eosina).

Patients with a previous history of cocaine abuse, coagulopathy, grave systemic or infective diseases and neoplastic pathologies were excluded from the study. All patients signed the informed consent and the study received approval from the local ethics committee.

Study Design

The patients were assigned alternately to two groups, A and B (A: checkup, medical therapy only; B: medical therapy and surgical reconstruction treatment) with each containing 23 patients. The assigning of patients to be subjected to treatment A or B was obtained by a random sequence of computer generated numbers. The medical treatment was based on the administration of an intranasal spray with a solution of salt-bromine-iodine thermal water (3 spurts per nostril 3 times daily) together with the nightly application of a nasal unguent based on vitamins (vitamins E, A, D-panthenol). Group B patients, before medical therapy, were subjected to an endoscopic reconstruction of inferior turbinates with PRP mixed with autologous fat (PRL). Both groups were requested to note every and any collateral effect that presented itself during the course of the study.

Preparation of Prp

The preparation process consisted of 3 phases: hemal extraction, centrifugation to obtain a concentrated platelet and activation [26]. Following hemal extraction from a peripheral vein, some sodium citrate as an anticoagulant was added to the blood (system of RegenLab, Le Mon-sur-Lausanne, Switzerland). The method of manual PRP preparation consists in a centrifugation of 1500 rpm for a total of 10 minutes which allowed the platelet to remain in suspension with the plasma while the leucocytes and erythrocytes settled on the bottom of the test tube. After the centrifugation the platelet and leucocyte buffy coat were extracted with 9ml of plasma [21]. Calcium chloride was added to the PRP as thus obtained to activate the platelet and stimulate the secretions of growth factors with emiocytosis of alpha granules.

Preparation of Fat

The purified fat was obtained after the transumbilical extraction with lipoaspiration microtubes (1.5mm in diameter) via centrifugation for 3 minutes at 3000 rpm (Coleman's technique) and inserted aseptically into a syringe of 1ml mixed with PRP. This procedure allowed a purified fat preserving the adipocytes in their entirety to be obtained, while separating the fluid components from those serosanguineous [24,25].

Procedure

Group B patients undergoing treatment were prepared 15 minutes before the reconstruction of turbinates with local anesthesia for mucosal contact with a cotton substance soaked in Lidocaine located along the full length of the inferior meatus. A nasal endoscope of 3mm 0° (Karl Storz, Tuttlingen, Germany) was used for a selective infiltration of turbinate compartments under endoscopic guidance. The PRL solution was injected, after their endoscopic identification, in the sites of previous cauterization regions or amputations of the previously tested turbinates with the positioning of pledgets soaked in a saline solution (Houser's test), via a syringe of 5ml with a spinal needle of 22G of 90mm. The procedure did not determine significant bleeding, with exceptions made for a modest quantity from the injection site (drops), which never required either nasal tamponing or suspension of the procedure.

Clinical Evaluation

At the beginning of the study (T0), every patient was requested to indicate the seriousness of subjective nasal symptoms on a VAS scale (0 min. -10 max.) (nasal obstruction, nasal discharge, sneezing, itching, pain). All patients were required to complete the SNOT-22 questionnaire before and after the treatment and the results were confirmed with regards the five most important questions. All patients underwent a basal anterior rhinomanometry (AAR) to evaluate their nasal resistance (Rhinomanometer Labat srl, Treviso, Italy) during the day. In accordance with the International Committee on Standardization of Rhinomanometry, the nasal airflow resistance was measured using a standard pressure (150 Pa) and the total nasal resistance was calculated by rhinomanometric monolateral registrations [27]. The AAR measuring was not carried out in the case the patient was affected by a common acute cold or a nasal allergy crisis, postponing the measuring to the end of the acute phase. The AAR measuring was performed on a seated patient after a 15-minute period of room acclimatization, in standard conditions of temperature and humidity. Each patient was assigned a rhinoendoscopic score with a 1-4 increasing gravity after at least one month of abstinence from medical therapy, carried out at the beginning and at the end of the study based on the evaluation (performed by the same examiner) of the volume of the nasal crusting in relation to the respiratory obstacle (from 1: flat crusting on the mucosal surface, minimally obstructing the respiratory lumen, to 4: bridge crusting between the nasal wall and completely obstructing septum). In order to obtain a functional piece of data on the nasal mucosal state in both groups under study, the Mucociliary Transport Time (MCTt) was calculated, before and after the treatment. All patients were subjected to MCTt nasal evaluation, using a vegetable carbon powder and saccharin mixture of 3%. The MCTt was calculated as the time interval between the moment in which the powder was positioned on

the head of the inferior turbinate (anterior compartment) up to when a stripe of the same powder appeared in the oropharynx during the direct pharyngoscopic examination [28]. The clearance time for saccharin was instead calculated taking the end of the test into consideration when the patient detected a sweet taste in the mouth. All evaluations and tests were repeated and compared with those basal ones after 12 months of treatment for both groups in the study. It was possible after more than 1 year of treatment in 3 patients from group B, to carry out a biopsy for histologic examinations of the region of the turbinate reconstructed with PRL in the course of other operations carried out for different reasons other than those of the nose. The sections of the turbinate mucosa of 5µm were prepared according to standard procedure after the inclusion of paraffin and after being stained with hematoxylin-eosin.

Statistical Analysis

The value P (Student test, with statistical significance for $p < 0.05$) was utilized for all subjective and objective parameters. The statistical analysis was undertaken with SPSS (software package for statistical analysis) version 17.0 (Chicago, IL, USA).

Results

The study included 46 patients aged between 32-67 (table 1, 2). The medical therapy did not determine any collateral effects in any of the patients from either group in the study. Patients from group B did not report pain during or after the procedure, with the exception made for few sporadic cases of nasal burns and minimal discharge mixed with blood after nose-blowing, for which paracetamol when required (500mg tablets) was prescribed in the postoperative period without any adverse consequences reported. In particular, no cases of epistaxis, nor any general or local complications in the nasal sites treated with PRL (synechia, crusting formation) were found. The area of umbilical fat removal was healed without residue and the stitching (nylon 5-0) was removed in 5-7 postoperative days. With regards the subjective nasal symptoms and the endoscopic nasal objectivity, when compared with the after treatment, a statistically significant improvement in group B ($p < 0.05$) was noted (table 3). Concerning the objective rhinomanometric evaluation when compared to post-treatment, a trend similar to what had been observed in subjective nasal symptoms was noted, with an improvement in favour of group B that had been treated with PRL ($p < 0.05$) (table 4). The comparative results between the two groups A and B of MCTt have shown a statistically notable variation revealing a greater efficacy of the treatment with PRL compared with that sole medical one in the improvement in the mucociliary function (table 4). The comparison between groups A and B before and after treatment according to the SNOT-22 questionnaire with regard to the most important 5 questions, showed an improvement for both groups under study but with more favourable efficacy

results for group B (table 5).

	Group A (n=23)	Group B (n=23)	p-value
Age (years)	39.3 ±2.02	42.5 ±2.08	p>0.05
Sex			p>0.05
Male	18(82.6%)	20(86.9%)	
Female	5(17.4%)	3(13.1%)	

Table 1. Patients demographics data.

Group	A (n=23)	B (n=23)	p-value
Nasal obstruction (Mean ± SD)	9.19 ± 0.75	9.43 ± 0.71	p>0.05
Itch	7.19 ± 1.15	8.11 ± 0.98	p>0.05
Rhinorrhea	9.32 ± 1.10	9.45 ± 0.93	p>0.05
Sneezing	7.21 ± 1.12	7.50 ± 1.21	p>0.05
Pain	7.91 ± 1.11	7.60 ± 1.31	p>0.05
Clinic/Rhinoendoscopic Score			
1	0	0	p>0.05
2	3(13.1%)	3(13.2%)	
3	9(39.1%)	10(43.4%)	
4	11(47.8%)	10(43.4%)	

Table 2. Comparison between VAS and rhinoendoscopic score before treatment.

Group	Control A (n=23)	Treatment B (n=23)	p-value
Nasal obstruction (Mean ± SD)	7.15 ± 0.65	4.49 ± 0.61	p<0.05
Itch	6.11 ± 1.10	5.10 ± 0.78	p<0.05
Rhinorrhea	7.82 ± 0.60	5.35 ± 0.43	p<0.05
Sneezing	6.10 ± 1.11	5.20 ± 1.11	p<0.05
Pain	6.11 ± 1.10	4.90 ± 1.11	p<0.05
Clinic/Rhinoendoscopic Score			

1	0	10(43.4%)	p<0.05
2	4(17.4%)	13(56.6%)	
3	15(65.2%)	0	
4	4(17.4%)	0	

Table 3. Comparison of the results after treatment.

	Gr A	Gr B
AAR	1.23 ± 0.04 Pa/cc3/sec	1.11 ± 0.05 Pa/cc3/sec
MCTt	20.9 ± 2 min	21.45 ± 2 min

Pre-treatment

	Gr A	Gr B
AAR	1.08 ± 0.06 Pa/cc3/sec	0.57 ± 0.03 Pa/cc3/sec
MCTt	17.56 ± 2 min	14.5 ± 2 min

Post-treatment(difference between groups p<0.05)

Table 4. Comparison between AAR and MCTt pre and post-treatment.

	Gr A	Gr B
5 most important questions (mean)	24.2	23.3

Pre-treatment

	Gr A	Gr B
5 most important questions (mean)	16.2	10.8

Post-treatment (difference between groups p<0.05)

Table 5. Comparison of SNOT-22 for the 5 most important questions pre an post-treatment (mean).

Histologic Evaluations

According to the results of previous histologic experiences of the efficacy of PRP in animal and human studies, in the samples of our examined patients we have observed a satisfactory reconstruction of the mucosa and submucosa of the turbinate

after 12 months from the treatment with PRL compared with the preoperative checkup (Figure 3) [29,30]. Particularly the almost complete reepithelialization of the mucosal surface of the turbinate and the reduction of the inflammatory part of the submucosa have been observed in the areas subjected to a reconstruction with PRL.

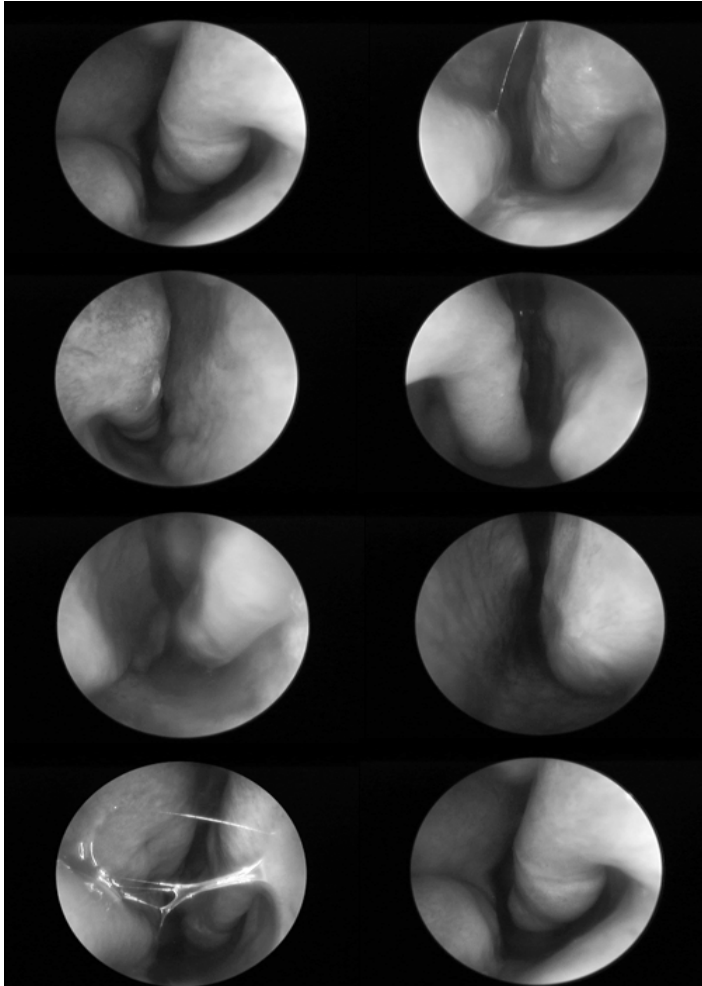


Figure 3. Turbinates pre and after treatment with PRL.

Discussion

The results allow us to conclude a greater efficacy of both medical therapy and infiltrative treatment with PRL, compared to the sole medical therapy in order to check the signs and symptoms of ENS-IT with the subtotal amputation of the inferior turbinates. With regards the nasal symptoms VAS evaluated, a greater efficacy has been shown in the checkup of the group of patients following treatment B. In particular the patients who received the treatment with PRL showed better objective parameters (RAA, endoscopic score) and with the SNOT-22, when compared to the group following the sole medical therapy. The improvement (at RAA) of group B, appears to be due to the smaller quantity of intranasal crusting

and consequently better air canalization in the patients treated with PRL. The results of the evaluation of MCTt document an improvement of the function of the mucosal surfaces of the turbinate after the reconstruction with PRL, which is very notable in a category of patients affected by ENS where the damage of the mucociliary clearance together with the mucosal atrophy represents the main invalidating pathogenic moment of the quality of life owing to the continuous formation and crusting stasis in the nasal cavity. In our experience, the association of PRP with adipose cells (PRL) has resulted in being one of the key points to the efficacy of the reconstructive treatment in terms of restoring functionality, since both the mixed components together contributed to the recovery both of the volume and the specific-site functionalities of the damaged or amputated nasal regions. It is possible to hypothesize that on the basis of the favourable results obtained there is a restoration of regional neovascularization where there has been a volumetric site-specific increase, which together with the regenerative powers of platelet GF have led to an objective and symptomatological improvement [31-33]. The surgical technique also showed itself to be extremely simple both rhinosurgically and for the extraction of the periumbilical fat, but above all, in accordance with previously published literature, without the collateral effects [34] and discomfort for the patient. The surgical approach we have described, with endoscopic technique and compartmental evaluation of the treated turbinate undersurface, allows a greater homogeneity of the classification of ENS-IT damage, together with a better evaluation of the obtained results after a certain period, with the presupposed essential sharing of clinical data among different centers and in order to guarantee the reproducibility of the methodology. Such a repair operation has been characterized by a very low invasiveness with a rapid postoperative period (day surgery) with easy availability to autologous biological tissue without the necessity of using other tissue from other anatomic sites as reported by other authors using different methodologies (nasal mucosa, muscular band, osteo-cartilaginous flaps, etc), and, above all, with no collateral effects. The basis of this regenerative surgery is represented by 3 elements: growth factors contained in a platelet gel, stem cells taken from adipose tissue (mixed with the PRP to obtain the PRL) and the biomaterials of synthesis (hyaluronic acid, collagen). The hemostatic capacity of platelets and their complex action mechanism (more than 300 proteins) is well-known, but only recently, owing to the progress of molecular biology could we minutely understand the different mechanisms which induced growth factors. Once activated, platelets release the growth factors contained in the alpha granules which are able to perform specific functions in the cell regeneration and in the development of the tissue where they have been liberated. In fact, the GF (growth factors) proteins are contained inside the platelets, factors of growth implicated in the regeneration of the tissue which have suffered damage. The PRP contains different typologies

of GF (isomers of the platelet GF transforming GF $\beta 1$ and $\beta 2$, GF insulin α and β , vascular endothelial GF) able to promote bone regeneration and to induce the differentiation of pluripotent cells. The GFs act as activation signals to attract clones of stem cells to the damage site and are contemporarily able to induce their proliferation. The action of GF on the osteoblasts is, for example, able to induce mitosis and to stimulate the migration of the mesenchymal cell progenitors. A notable aspect for its practical implication, is how the chemotactic and mitogenic stimulus of PRP on mesenchymal stem cells is able to determine the best reconstitution and regeneration of the damaged tissue in a directly proportional way with the platelet concentration (dose-dependent efficacy) [18,29,30,23]. The clinical effects of the PRP [35,36] on the implanted tissue can be summarized in a biostimulation with:

- cellular proliferation
- bioreparative and regenerative processes
- angiogenesis and revascularization of tissue
- proliferation of mesenchymal cells
- production of fibroblasts
- production of collagen

The clinical experience in the field of regenerative nasal surgery has shown a greater efficacy in the processes of the mucosal regeneration and its functionality with the activation of cellular proliferation and gain of volume. In conclusion, regenerative surgery in the nasal districts aims towards the more promising possibility of mini-invasive solutions of many problems linked to the defective functionality of the nose, particularly after previous demolitive operations (ENS or atrophic rhinitis), but also for the excessive use of inhaled stupeficient substances (cocaine) thanks to the capacity of the new mixture to help in rebuilding both the shape and the function of damaged anatomic areas. Our studies are evaluating possible further functional improvements in ENS after repeated sittings of infiltrations of PRL in the same treated undersurface areas from 6 and 12 months from the first infiltration [37] and the stability during the time of the results obtained.

Conclusions

The reconstruction with PRL of the inferior turbinates, associated with the topical medical therapies of washing and of using an emollient, has proved better able in a statistically notable way to improve the subjective nasal symptoms and objective rhinoscopic observations in a group of patients affected by ENS, particularly noting an improvement in the quality of the patient's life concerning the nasal complaints

measured by using SNOT-22.

Disclosure Information

The authors state to have no actual or potential conflict of interest in relation to this paper. They didn't receive funds (grants, consulted fees, honorarium, travel reimbursements, medicines, equipment, or administrative support) from a third party to support the work (such as government granting agency, charitable foundation or commercial sponsor).

References

1. Di Rienzo Businco L, Di Rienzo Businco A, Lauriello M. Comparative study on the effectiveness of Coblation-assisted turbinoplasty in allergic rhinitis. *Rhinology*. 2010, 48(2):174-178.
2. Di Rienzo Businco L, Laurino S, Di Rienzo Businco A, Ventura L, Lauriello M. Turbinoplasty with Quantic Molecular Resonance in the treatment of persistent moderate-severe allergic rhinitis: comparative analysis of efficacy. *American Journal Rhinol Allerg*. 2014, 28(2): 164-168.
3. Lauriello M, Di Rienzo Businco L, Bonini S, Alessandra Micera, Paola Muzi. TLR4 and TLR9 Expression in Different Phenotypes of Rhinitis. *Int J Otolaryngol*. 2012, 2012(2012): 925164.
4. Addolorato G, Ancona C, Capristo E, Graziosetto R, Di Rienzo L et al. State and trait anxiety in women affected by allergic and vasomotor rhinitis. *J Psychosom Res*. 1999, 46(3): 283-289.
5. Houser SM. Surgical treatment for empty nose syndrome. *Arch Otolaryngol Head Neck Surg*. 2007, 133(9): 858-863.
6. Sozansky J, Houser SM. Pathophysiology of Empty Nose Syndrome. *Laryngoscope*. 2015, 125(1): 70-74.
7. Baraniuk JN. Subjective nasal fullness and objective congestion. *Proc Am Thorac Soc*. 2011, 8(1): 62-69.
8. Scheithauer MO. Surgery of the turbinates and "empty nose" syndrome. *GMS Curr Top Otorhinolaryngol Head Neck Surg*. 2010, 9: Doc03.
9. Eccles R, Morris S, Tolley NS. The effects of nasal anesthesia upon nasal sensation of airflow. *Acta Otolaryngol*. 1988, 106(1-2): 152-155.
10. Zhao K, Jiang J, Blacker K, Lyman B, Dalton P. Regional peak mucosal cooling predicts the perception of nasal patency. *Laryngoscope*. 2014, 124(3): 589-595.
11. Modrzynski M. Hyaluronic acid gel in the treatment of emp-

- ty nose syndrome. *Am J Rhinol Allergy*. 2011, 25(2):103–106.
12. Businco LD, Lauriello M, Marsico C, Corbisiero A, Cipriani O, et al. Psychological aspects and treatment of patients with nasal septal perforation due to cocaine inhalation. *Acta Otorhinolaryngol Ital*. 2008, 28(5): 247-251.
 13. Jung JH, Baguindali MA, Park JT, Jang YJ. Costal cartilage is a superior implant material than conchal cartilage in the treatment of empty nose syndrome. *Otolaryngol Head Neck Surg*. 2013,149(3): 500–505.
 14. Papay FA, Eliachar I, Risica R. Fibromuscular temporalis graft implantation for rhinitis sicca. *Ear Nose Throat J*. 1991, 70(6): 381–384.
 15. Chenyan Jiang, Runjie Shi, Yiyuan Sun. Study of inferior turbinate reconstruction with medpor for the treatment of Empty Nose Syndrome. *Laryngoscope*. 2013, 123(5):1106–1111.
 16. Rice DH. Rebuilding the inferior turbinate with hydroxyapatite cement. *Ear Nose Throat J*. 2000, 79(4): 276–277.
 17. Saafan ME. Acellular dermal (alloderm) grafts versus silastic sheets implants for management of empty nose syndrome. *Eur Arch Otorhinolaryngol*. 2013, 270(2): 527–533.
 18. Anitua E, Andia I, Ardanza B, Nurden P, Nurden AT. Autologous platelets as a source of proteins for healing and tissue regeneration. *Tromb Haemost*. 2004, 91(4): 4-15.
 19. Cervelli V, Gentile P, Scioli MG, Grimaldi M, Casciani CU et al. Application of platelet-rich plasma in plastic surgery: Clinical and in vitro evaluation. *Tissue Eng Part C Methods*. 2009,15(4): 625– 634.
 20. Lane MD, Tang QQ. From multipotent stem cell to adipocyte. *Birth Defects Res A Clin Mol Teratol*. 2005, 73(7): 476–477.
 21. Cervelli V, Gentile P, Grimaldi M. Regenerative surgery: Use of fat grafting combined with platelet-rich plasma for chronic lower-extremity ulcers. *Aesthetic Plast Surg*. 2009, 33: 340–345.
 22. Cervelli V, Gentile P. Use of cell fat mixed with platelet gel in progressive hemifacial atrophy. *Aesthetic Plast Surg*. 2009, 33(1): 22–27.
 23. Cervelli V, Gentile P, De Angelis B, Calabrese C, Di Stefani A et al. Application of enhanced stromal vascular fraction and fat grafting mixed with PRP in posttraumatic lower extremity ulcers. *Stem Cell Res*. 2011, 6(2):103–111.
 24. Coleman SR. Facial recontouring with lipostructure. *Clin Plast Surg*. 1997, 24(2): 347–367.
 25. Coleman SR. Long-term survival of fat transplants: Controlled demonstrations. *Aesthetic Plast Surg*. 1995, 19(5): 421– 425.
 26. Kevy SV, Jacobson MS. Comparison of methods for point of care preparation of autologous platelet gel. *J Extra Corpor Technol*. 2004, 36(1): 28 –35.
 27. Clement PAR, Godts F, Standardisation Committee on Objective Assessment of the Nasal Airway, IRS, and ERS. Consensus report on acoustic rhinometry and rhinomanometry. *Rhinology*. 2005, 43(3):169-179.
 28. Passali D, Mezzedimi C, Passali GC, Nuti D, Bellussi L et al. The role of rhinomanometry, acoustic rhinometry, and mucociliary transport-time in the assesment of nasal patency. *Ear Nose Throat J*. 2000, 79(5):397-400.
 29. Pieri F, Lucareli E, Corinaldesi G, Iezzi G, Piattelli A et al. Mesenchymal stem cells and platelet-rich plasma enhance bone formation in sinus grafting: a histomorphometric study in minipigs. *J Clin Periodontol*. 2008, 35(6): 539-546.
 30. Warnke PH, Springer IN, Wiltfang J, Acil Y, Eufinger H et al. Growth and transplantation of a custom vascularized bone graft in a man. *Lancet*. 2004, 364(9436): 766-770.
 31. Prunet-Marcassus B, Cousin B, Caton D, André M, Pénicaud L et al. From heterogeneity to plasticity in adipose tissues: Site-specific differences. *Exp Cell Res*. 2006, 312(6): 727–736.
 32. Cao Y, Sun Z, Liao L, Meng Y, Han Q et al. Human adipose tissue-derived stem cells differentiate into endothelial cells in vitro and improve postnatal neovascularization in vivo. *Biochem Biophys Res Commun*. 2005, 332(2): 370 –379.
 33. Matsumoto D, Sato K, Gonda K, Shigeura T, Sato T et al. Cell-assisted lipotransfer: Supportive use of human adipose-derived cells for soft tissue augmentation with lipoinjection. *Tissue Eng*. 2006,12(12): 3375–3382.
 34. Gutowski KA, ASPS Fat Graft Task Force. Current applications and safety of autologous fat grafts: A report of the ASPS fat graft task force. *Plast Reconstr Surg*. 2009,124(1): 272–280.
 35. Man D, Plosker H, Winland-Brown JE. The use of autologous platelet-rich plasma (platelet gel) and autologous platelet-poor plasma (fibrin glue) in cosmetic surgery. *Plast Reconstr Surg*. 2001,107(1): 229-237.

36. Marlovits S, Mousavi M, Gabler C, Erdös J, Vécsei V. A new simplified technique for producing platelet-rich plasma: A short technical note. *Eur Spine J.* 2004, 13(suppl 1): S102–S10.
37. Zhu M, Zhou Z, Chen Y, Schreiber R, Ransom JT et al. Supplementation of fat grafts with adipose-derived regenerative cells improves long-term graft retention. *Ann Plast Surg.* 2010, 64(2): 222–228.